

# Northumbria Research Link

Citation: Skarparis, Katy and Ford, Claire (2018) Venepuncture in adults. British Journal of Nursing, 27 (22). pp. 1312-1315. ISSN 0966-0461

Published by: Mark Allen Publishing

URL: <https://doi.org/10.12968/bjon.2018.27.22.1312>  
<<https://doi.org/10.12968/bjon.2018.27.22.1312>>

This version was downloaded from Northumbria Research Link:  
<http://nrl.northumbria.ac.uk/id/eprint/36907/>

Northumbria University has developed Northumbria Research Link (NRL) to enable users to access the University's research output. Copyright © and moral rights for items on NRL are retained by the individual author(s) and/or other copyright owners. Single copies of full items can be reproduced, displayed or performed, and given to third parties in any format or medium for personal research or study, educational, or not-for-profit purposes without prior permission or charge, provided the authors, title and full bibliographic details are given, as well as a hyperlink and/or URL to the original metadata page. The content must not be changed in any way. Full items must not be sold commercially in any format or medium without formal permission of the copyright holder. The full policy is available online: <http://nrl.northumbria.ac.uk/policies.html>

This document may differ from the final, published version of the research and has been made available online in accordance with publisher policies. To read and/or cite from the published version of the research, please visit the publisher's website (a subscription may be required.)

# **Venepuncture (adult): At a glance**

Written by

Dr Katy Skarparis – Lecturer, Adult Nursing, Northumbria University

&

Claire Ford - Lecturer, Adult Nursing, Northumbria University

This article will:

- Provide clinical guidance on venepuncture on an adult
- Increase knowledge on the anatomical structures associated with venepuncture
- Demonstrate the clinical procedural technique of venepuncture
- Provide an awareness of the dangers and complications of this invasive technique

## **Why do healthcare professionals need to learn how to conduct venepuncture?**

Venepuncture is a vital procedure that is routinely used in the care and management of patients and is one of the most commonly performed invasive procedure (Boyd, 2013). It enables healthcare professionals to obtain a sample of blood, by the puncture of a vein with a hollow-bore needle, vacuum system or butterfly infusion system in order to obtain a sample of blood for analysis (Thomas, 2015). These investigations typically include biochemical to analyse certain parameters, such as potassium and sodium levels, haematological to determine blood measurements and microbiological to determine the presence of pathogens (Gallagher, 2015). As this is a procedure, which nurses may be asked to perform as part of their role, it is essential that they are adequately trained, competent in using the correct technique and aware of any

advances or changes in the underpinning evidence (Nursing and Midwifery Council (NMC), 2015).

### **Informed consent and patient preparation**

Before carrying out venepuncture, and where possible, it is necessary to obtain informed consent. It is also imperative at this point to gauge how the patient is feeling about the procedure, as gaining an insight into potential fears, (i.e. fear of needles – trypanophobia) (Chinn, 2014), anxieties or preferences will allow for adequate preparation of the patient and the environment prior to the procedure. This can be achieved by asking questions such as “have you had this procedure before” and “how do you feel about the procedure”. Any potential allergies also need to be determined prior to gathering the equipment, as alternative gloves and dressings may be required.

### **Anatomy of the arm**

When undertaking venepuncture, it is important to understand the anatomy and physiology of the veins, circulation and surrounding structures (arteries and nerves), in order to undertake safe and effective practice (McCall and Tankersley, 2012). The superficial veins (Median Cubital, Cephalic, and Basilic) found in the antecubital fossa region of the arms, are the most commonly selected sites for venepuncture (see image 1), as they are easily accessible and cause minimal discomfort for the patient (Brooks, 2017). Metacarpal veins (see image 2) can also be used as they are easy to visualise, and palpate; however, the use of these veins may be more painful and difficult in patients with poor skin turgor (McCall and Tankersley, 2012).

### **Choosing the correct site and vein**

Although the arm is the most commonly used site for venepuncture, it is important to assess the most appropriate site for each individual patient. Factors that influence the decision include patient preference, past medical history, age, current comorbidities, skin condition, vein

suitability and accessibility and reasons for use (Gorski *et al.*, 2016). Additionally, it is essential to consider which arm or limb to use, which vein to select within that limb and then which particular site on the skin (see figure 3).

## **Equipment**

There are a wide variety of hollow-bore needles and vacuum system that are available for venepuncture; therefore, it is imperative that you familiarise yourself with the equipment that is used by your Trust. See (figure 4) for an example list of the equipment that is required.

## **Vacutainers and order of draw**

Traditionally, blood samples were obtained by needle and syringe, but advancements in technology and medical devices as seen this being superseded by vacutainer systems (Blann and Ahmed, 2014). These glass tubes contain a partial vacuum, which encourages the movement of blood from the vein into the tube, and the amount of vacuum present will determine the amount of blood required within the vacutainer (Dougherty and Lister, 2015). As well as the vacuum, the tubes also contain additives or anticoagulants, such as, sodium citrate, lithium heparin, and serum, and which one is used is dependent upon which analysis techniques are to be conducted in the laboratory (Blann and Ahmen, 2014). In order to mix the blood with the contents of the vacutainers, the tubes must be inverted, and the number of inversions will depend upon manufactures instructions (Dougherty and Lister, 2015). It is also essential that the additives within the various tubes are not mixed, and therefore if more than one tube it to be used; these must be used in a specific order (Thomas, 2015). (Higgins, 2013) concurs, claiming that within the blood analysis continuum, errors during the collection of the

samples is where the most errors occur. Order of draw protocols should, therefore, be adhered to.

### **Tourniquets**

Within practice tourniquets can be used as a means of maximising successful attempts on first insertion (Shaw, 2014). Several types can be found in practice, these should be disposable, easy to use and latex-free (Dougherty and Lister, 2015). When applying the tourniquet, it is also imperative that it is removed as soon as possible (not exceeding sixty seconds), as this will cause venous stasis, localised acidemia and haemoconcentration, which affect the blood for analysis (Pagan and Pagana, 2011; Higgins, 2013). Consequently, Gorski *et al.* (2016) do not advocate the use of a tourniquet, stating that it should be avoided if possible. Therefore, practice may differ and it is imperative that you abide by local trust policy when deciding if a tourniquet is to be used.

### **Site preparation**

Although there is some controversy about whether skin cleansing of the site is necessary, latest guidelines by Gorski *et al.* (2016) state that skin antisepsis should be performed prior to all venepunctures to prevent the risk of infection. It can be prepared with a cleansing agent which is alcohol based, such as, 70% isopropyl alcohol or 2% chlorhexidine in 70% alcohol (Loveday *et al.*, 2014). The technique for how the skin should be prepared, must in accordance with the manufacturers instructions, which will be specific to the products being used.

### **Risks and hazards**

As with any clinical procedure, the trained healthcare professional must be aware of the risks involved, for themselves, the patient and others. Further details in relation to blood-borne infection, sharps safety, phlebitis, arterial puncture and extravasation can be found in the accompanying article entitled '*Cannulation: At a glance*' (Ford, 2018).

## **What is the correct procedure for venepuncture?**

As healthcare professionals, it is important to work within guidelines and policies, and use evidence-based practice (NMC, 2015). The use of standard Aseptic Non-Touch Technique (ANTT) for preparation and performance of the procedure can minimise the risk of contamination and risk of infection (Loveday *et al.*, 2014).

1. Communicate with the patient, gain informed consent and ascertain preferences, allergies and fears.
2. Decontaminate hands and gather and assemble relevant equipment. (see figure 5.1)
3. Place the limb in a comfortable, accessible position (use a pillow if necessary).
4. To assess which vein to utilise, a tourniquet can be used to make the veins more visible. Make sure the tourniquet is appropriately applied 7-10cm above the chosen site. However, it should only be tight enough to impede venous return and not obstruct arterial flow. Asking the patient to open and close their fist, or using gravity and hanging the patient arm down, may also encourage venous filling.
5. Palpate with two fingers or the thumb, to find the best available vein. (see figure 5.2)  
N.B. Veins do not pulsate.
6. Decontaminate hands and apply PPE.
7. Clean the chosen site with the alcohol-based preparation equipment and allow to dry. (see figure 5.3) Do not re-palpate, as this will increase the risk of contamination.
8. Remove the sheath from the needle and inspect for damage.
9. Warn the patient they will feel a sharp scratch
10. Use one hand to apply traction on the skin a few centimetres below the site and avoid touching the clean area. (see figure 5.4)
11. With the bevel upwards, insert the needle at about a 10-30 degree angle, (this will vary depending upon the manufacturing guidelines). Some needle equipment will allow you

to see if you are correctly situated in the vein with a visual flashback - if this is not the case you will have to attach the vacutainer to observe for successful blood flow.

12. Attach the bottle/vacutainer to the device connected to the end of the needle (plastic holder). (see figure 5.5).
13. Allow the required blood, for that specific vacutainer to be collected in the glass vile, and as soon as blood runs freely, release the tourniquet. (see figure 5.6)
14. Remove vacutainer and invert as per manufacturing instructions.
15. Once all the required blood has been obtained, hover the gauze over the needle site (do not press down).
16. Retract the needle and put pressure on the site with the gauze.
17. Click the safety cap (over the needle) with your thumb and dispose of in the sharps container.
18. Remove PPE, wash hands, label specimens and document the care, noting any witnessed difficulties.

### **Top tips**

The following information has been collated by Northumbria University staff in relation to some of the common errors that students encounter when undertaking venepuncture.

1. Missed Vein – ensure you use your fingers to anchor the vein, this will stop the vein from moving and will also stretch the skin for better visibility. If you also choose one of the largest veins, then the likelihood of missing the vein will be reduced.
2. Blood spray – ensure you advance the needle tip far enough into the vein, if the tip has entered before the rest has advanced under the skin, you have only achieved partial needle insertion, and leakage may occur. Avoid superficial veins to help reduce this from occurring.

3. Blood stops flowing - This is probably due to the angle of insertion or if the tip of the needle has made contact with a valve, the vein wall or if the vein has collapsed. To remedy, gently advance or reposition the needle.
4. Spatter of blood that then stops - You have possibly pushed the needle too far, and it has exited the vein on the posterior side. Remove the needle and apply pressure.



### Image 1

Insert an anatomical diagram of the (Median Cubital, Cephalic, and Basilic veins).

### Image 2

Insert anatomical diagram of the metacarpal veins.

### Images 3

Arm/hand selection	Vein selection	Sites selection
<ul style="list-style-type: none"><li>• Avoid arms affected by a CVA</li><li>• Avoid arms impacted post mastectomy or node dissection</li><li>• Avoid arms affected by lymphoedema</li><li>• Choose arms / hands with good capillary refill</li><li>• Non-dominant arm (if this is patient's preference)</li></ul>	<ul style="list-style-type: none"><li>• Veins which are easily palpable</li><li>• Veins with largest diameter</li><li>• Avoid fragile and sclerosed veins</li><li>• Avoid veins irritated from previous use</li><li>• Avoid visible valves</li><li>• Avoid veins with fibrosis</li><li>• Avoid veins close to arteries</li></ul>	<ul style="list-style-type: none"><li>• Avoid sites affected by intravenous drug use</li><li>• Avoid sites with haematomas, oedema, or thrombus</li><li>• Avoid sites with a fistulae or vascular graft</li><li>• Avoid areas of inflammation</li><li>• Avoid areas with burns or scars</li></ul>

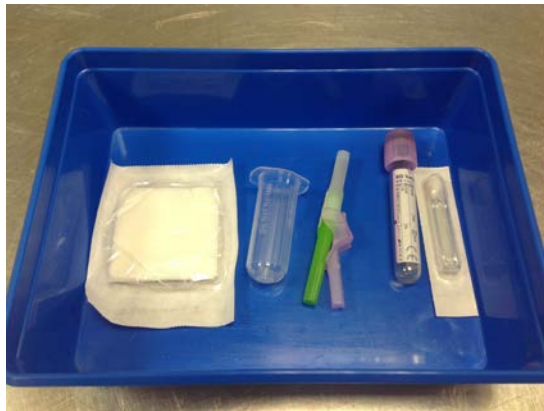### Image 4

Gloves	Apron	Alcohol gel	Procedural tray	Disposable tourniquet
Alcohol -based cleansing product	Needle	Tube Holder	Vacutainer bottles	Sterile gauze
Dressing or adhesive tpe	Sharps disposal bin	Request forms (signed, dated and labelled)	Pillow	

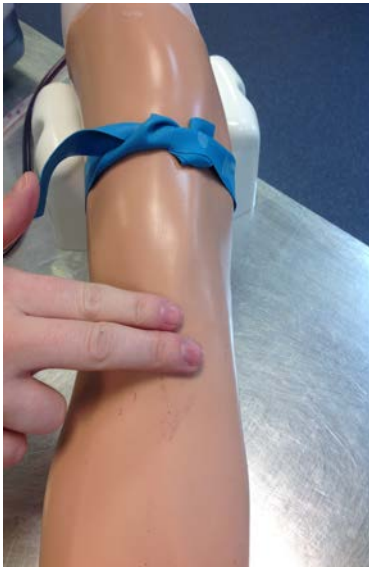(Dougherty and Lister, 2015)

**Images (property of Northumbria University)**

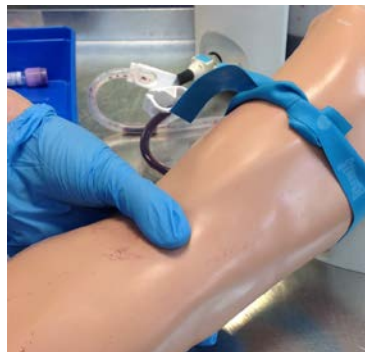**Image 5.1**



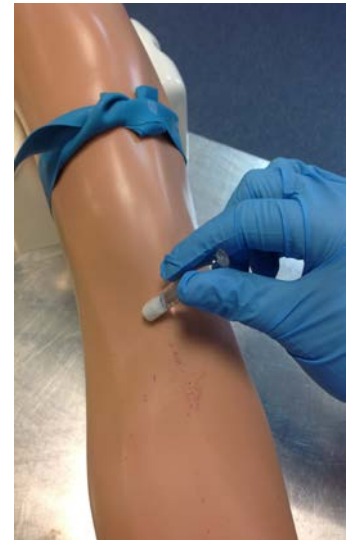**Image 5.2**



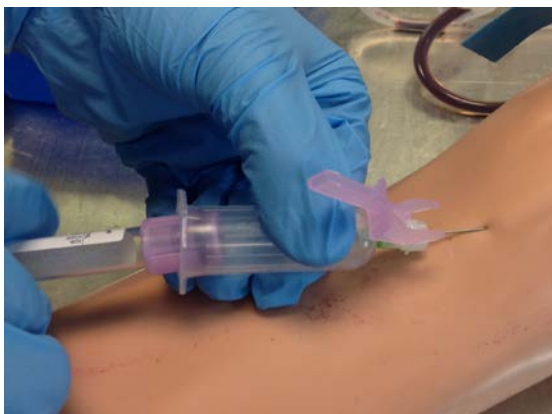
**Image 5.4**



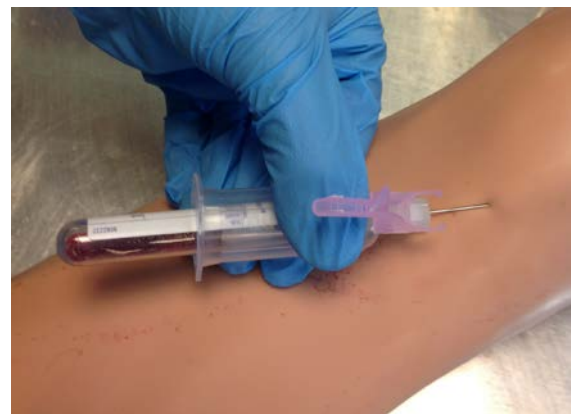**Image 5.3**



**Image 5.5**



**Image 5.6**



## **Reference List:**

- Blann, A. and Ahmed, N. (2014) *Blood Science: the principles and pathology*. West Sussex: Wiley.
- Boyd, C. (2013) *Clinical skills for nurses*. West Sussex: Wiley.
- Brooks, N. (2017) *Venepuncture & Cannulation: A practical guide*. 2<sup>nd</sup> edn. Keswick: M&K Update Ltd.
- Buowari, O. Y. (2013) 'Complications of venepuncture', *Advances in Bioscience and Biotechnology*, 4, pp. 126-128.
- Chinn, A. (2014) 'Specimen Collection', in Perry, A. G., Potter, P. A. and Ostendorf, W. R. (eds.) *Clinical Nursing skills and techniques*. 8<sup>th</sup> edn. Missouri, pp. 1052-1098
- Dougherty L, and Lister S. (2015) *The Royal Marsden Hospital manual of clinical nursing procedures*. 9<sup>th</sup> edn. West Sussex: Wiley.
- Gallagher, R. (2015) 'Aseptic technique and specimen collection', in Delves-Yates, C. (ed.) (2015) *Essentials of Nursing Practice*. London: Sage, pp. 403-422.
- Gorski, L. *et al.* (2016) 'Infusion Therapy: Standards of Practice', *Journal of Infusion Nursing*, 39(1S0), pp. S1-S169).
- Higgins, C. (2013) *Understanding laboratory investigations: A guide for nurse, midwives and healthcare professionals*. 3<sup>rd</sup> edn. West Sussex: Wiley.
- Loveday, H. P., Wilson, J. A., Pratt, R. J., Golsorkhi, M., Tingle, A., Bak, A., Browne, J., Prieto, J. & Wilcox, M. (2014). epic3: National Evidence-Based Guidelines for Preventing Healthcare-Associated Infections in NHS Hospitals in England. *Journal of Hospital Infection*, 86, pp. 1-70.
- McCall, R. E. and Tankersley, C. M. (2012) *Phlebotomy Essentials*. 5<sup>th</sup> edn. Oxford: Oxford University Press.
- NMC (2015) *The Code*. London: NMC.

- Pagana, K. D. and Pagana, T. J. (2011) *Mosby's diagnostic and laboratory test reference*. 10<sup>th</sup> edn. Missouri: Elsevier.
- Shaw, S. J. (2016). Locating difficult veins for venepuncture and cannulation. *Nursing Standard*, 31(25) pp. 62-71.
- Thomas, R. K. (2015) *Practical Medical procedures at a glance*. West Sussex: Wiley.